

USAGE OF FEMORAL HEAD ALLOGRAFT FOR AUGMENTATION OF HINDFOOT FUSION IN CHARCOT FOOT ARTHROPATHY: A CASE REPORT

Mohd Yazid B¹, Adrian T¹, Norliyana M¹, and Husna MA¹.

¹Department of Orthopaedic and Traumatology, Faculty of Medicine, National University of Malaysia, Kuala Lumpur.

Correspondence:

Mohd Yazid bin Bajuri,
Department of Orthopaedic and Traumatology,
Faculty of Medicine,
National University of Malaysia, Kuala Lumpur.
Email: ezeds007@yahoo.com.my

Abstract

Charcot arthropathy is a complex disease secondary to neuropathic foot caused by a multitude of diseases. However, the prevalent underlying disease is diabetes mellitus. The cascade of continuous bone destruction and remodeling leads to further bone deformities which if left untreated, may develop into infection and ultimately leading to amputation of the limb. As the majority of cases present at a much later stage, there is often significant bone loss further complicating treatment options. Despite the severe deformity, literature has shown good functional results with appropriate surgical treatment as in our case of Charcot arthropathy treated with ankle arthrodesis augmented with a femoral head bone graft which resulted in well healed wound with no signs of infection and good callus formation. Use of an allograft bone block in cases with extensive bone lost remains a significant option and facilitates patients who undergo surgery to fare better despite nonunion.

Keywords: Charcot Arthropathy, Femoral Head Bone Block, Hindfoot Nail

Introduction

Charcot foot arthropathy is a condition involving the bones and joints in a foot with peripheral neuropathy. The aim of treatment is to get a plantigrade, painless, stable and shoeable foot. There are significant challenges when approaching such a case including major bone defects. Arthrodesis is the mainstay of treatment in limb salvage surgery, however it may prove difficult as the results may be unsatisfactory if the bone defect is not addressed adequately.

Case presentation

A 48-years old, male with a previous history of end stage renal failure, gout and diabetes presented with a 3-month history of swelling over the left foot. Previously, he had similar swelling of the foot which regresses spontaneously. As a result of the previous swelling, the foot ended up deformed which alters his gait leading to functional disturbance. He could otherwise ambulate without support and the deformity does not cause any pain. He has no history of trauma or fever. Initial investigations showed no increase of inflammatory markers. Plain radiographs revealed osteolysis and deformity of the hind and mid foot. The talar bone was deficient and there was bone defect over the calcaneum due to articulation of the tibia with the calcaneum as seen in figure 1.

After consent has been obtained from the patient and his family members, we proceeded with fusion of the left hindfoot to correct the alignment of the hindfoot augmented by a cadaveric femoral head (Figure 2) as a bone graft. The femoral head was prepared prior to surgery through gamma irradiation and kept in the bone bank until needed. During the surgery, the chondral cartilage of the femoral head was removed using a bone nibbler and later was used as augmentation to fill up the gap that has been created by the deficient talus. A hindfoot arthrodesis nail was used to complete the procedure, locking the alignment of the hindfoot. Post-operatively, there were no complications noted and the patient underwent rehabilitation which includes a period of non-weight bearing until fusion had occurred. Figure 3 of immediate postoperative radiographs of left ankle show hindfoot arthrodesis nail in-situ. The wound was well healed with no signs of infection and good callus formation was seen within 4 months (Figure 4). Overall, the patient was satisfied with the operative outcome. Patient was under our follow-up up to 1 year and 6 months and able to ambulate with walking frame without any pain. Patient was supposed to come after 2 years of operation but was informed by the family members that the patient passed away due to heart failure secondary to pulmonary oedema.

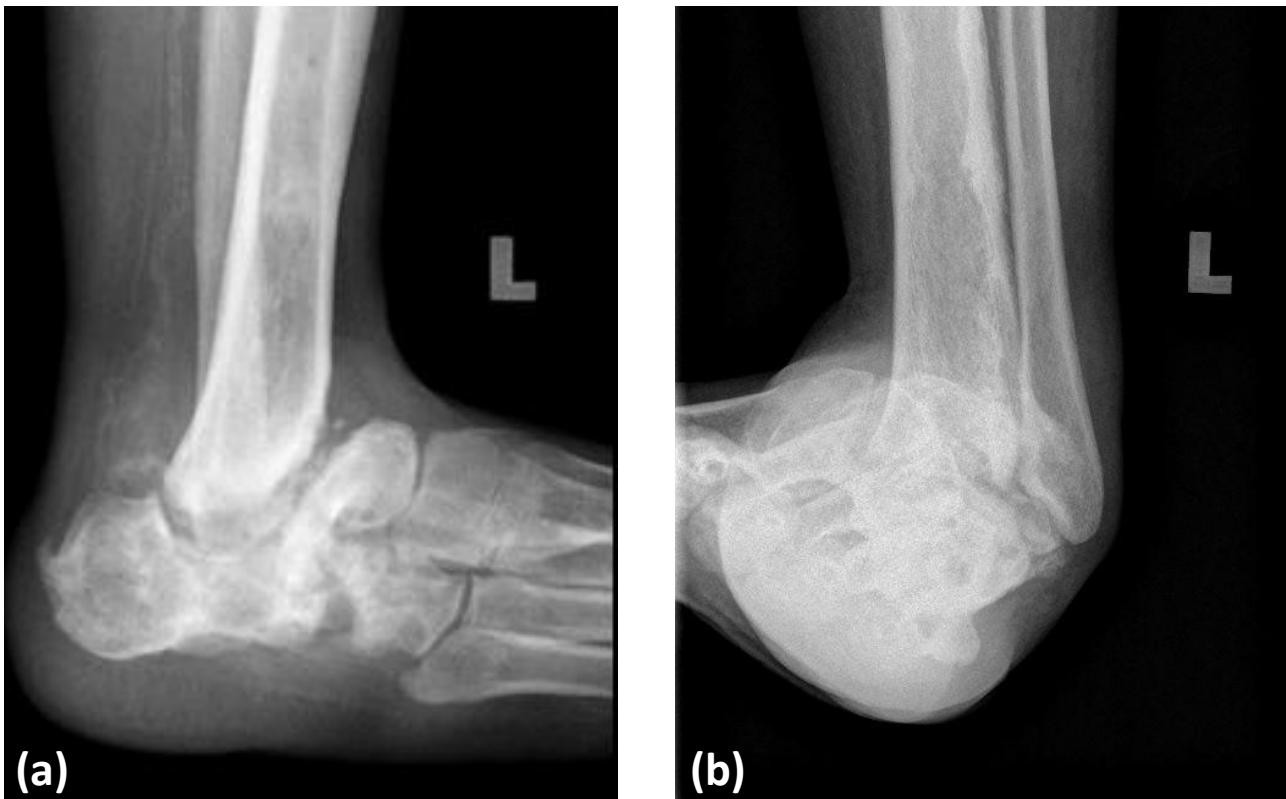


Figure 1: (a) Lateral view and (b) AP view of plain radiographs of the ankle show bony destruction and osteolysis of the talus and the surrounding structures causing hindfoot and midfoot deformity

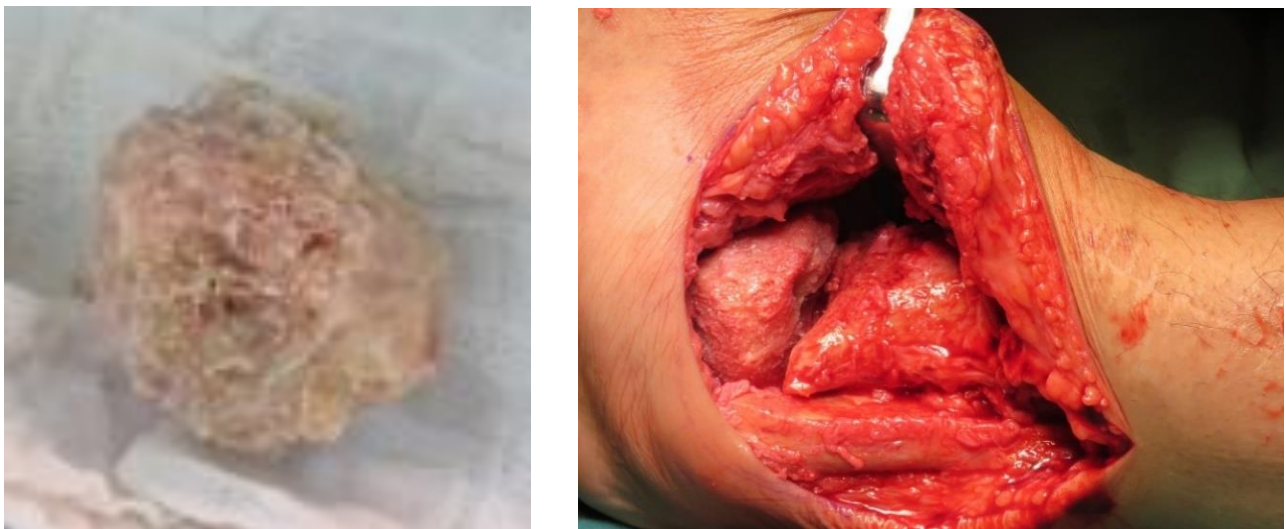


Figure 2: (a) Preparation of the femoral head involves denuding and removing all cartilaginous tissues (b) The femoral head bone graft is placed in the ankle to replace the deficient talus

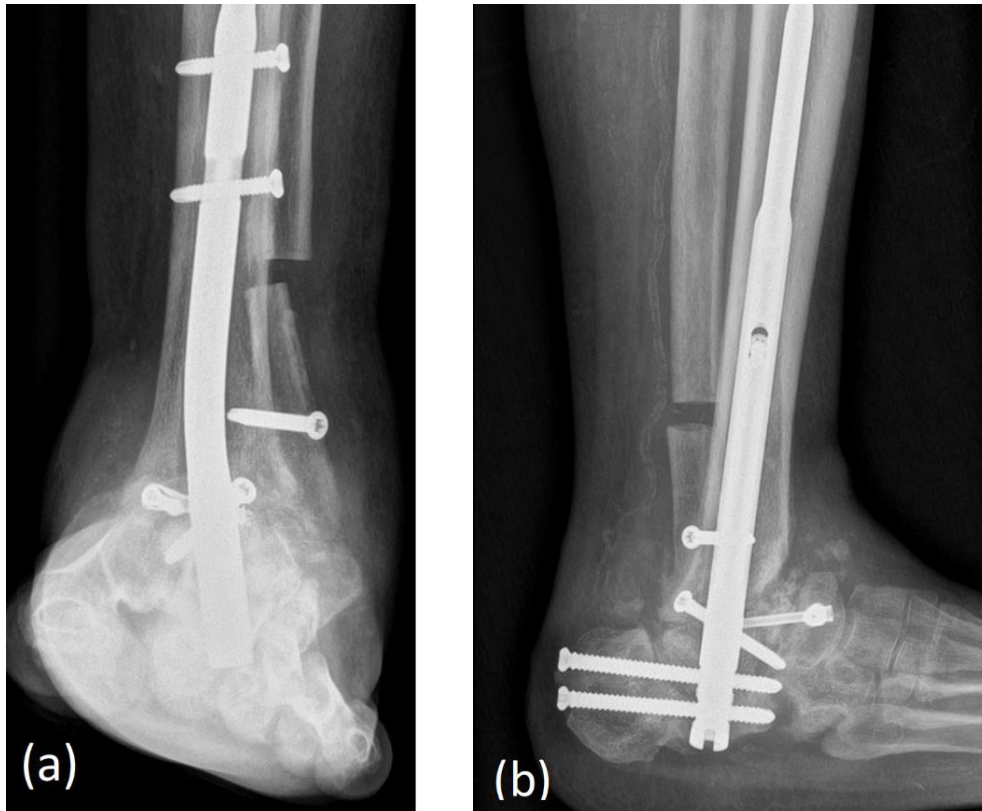


Figure 3: (a) AP view and (b) Lateral view of immediate postoperative radiographs of left ankle show hindfoot arthrodesis nail in-situ

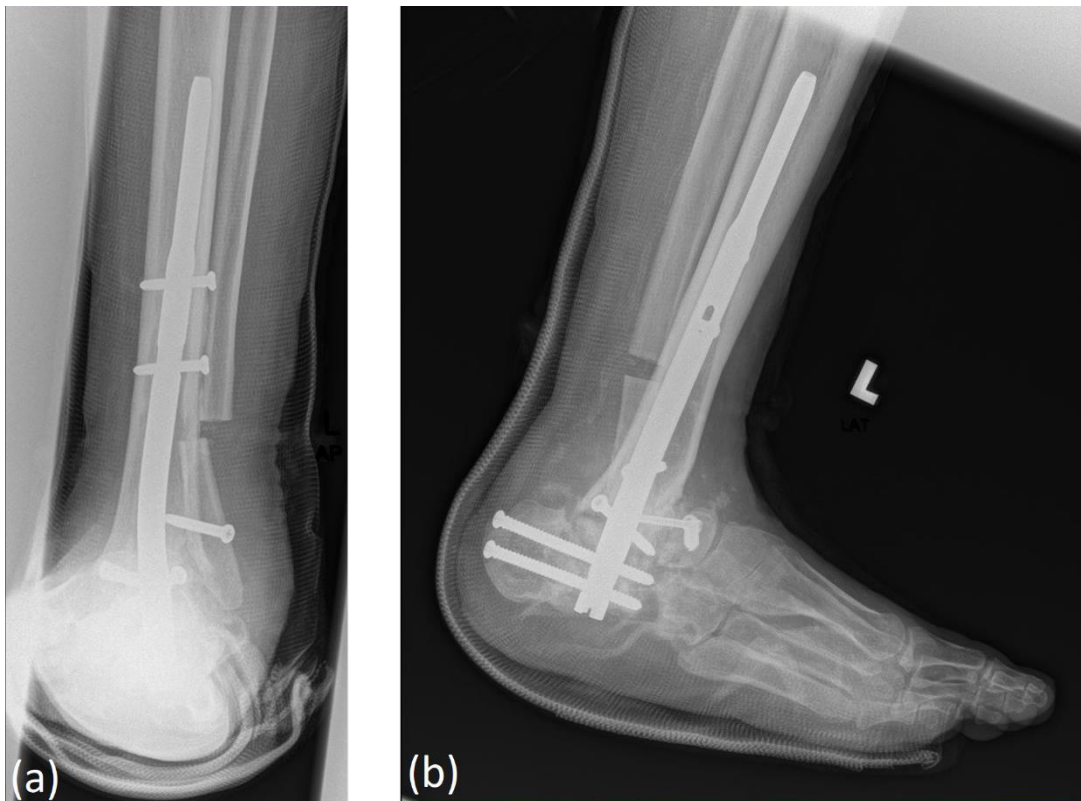


Figure 4: (a) AP view and (b) Lateral view of postoperative 4 months' radiographs of left ankle show good callus formation

Discussion

The Charcot foot is a debilitating condition characterized by pathological fractures, dislocations or subluxations that disrupts the bony architecture of the ankle and foot (1). The deformities may lead to chronic ulceration, infection, or osteomyelitis. In the presence of infection, there will be an increase in parameters such as high sensitivity C-reactive protein (hs-CRP) which was found to be single most reliable marker alongside procalcitonin and white blood cells (2). Initial treatment includes broad-spectrum antimicrobials followed by specific antibiotics after culture and sensitivity testing (3). However, if infection is severe, the limb may require amputation (1).

Adams was the first who described arthrodesis of both ankle and subtalar joints using an intramedullary nail in 1948 (4). Constructs would include intramedullary rod, plate and screws, or a combination of both. Results of fixation were however varied and literature in using femoral head graft as an augmentation to fusion are limited. The aim of reconstruction is to create a stable plantigrade foot in order to re-align the ankle and reduce the risk of ulceration therefore, reducing the morbidity and risk of amputation (1).

The femoral head bone block integrates through creeping substitution occurring at the outer surface of the graft (5). Revascularization was also found to be very slow despite compression of the femoral head graft to the tibial surface. Some studies have shown that large, incompletely filled osteons were still present in the graft 3 years after implantation (5). Other studies reported 50% radiographic fusion rate for tibiototalcalcaneal arthrodesis using a femoral head allograft (6). Poor fusion was however attributed to a high infection rate that may be due to uncontrolled premorbid conditions (6).

Jeng et al. (7) observed that fusion rates were dependent on a multitude of factors include diabetic control, previous history of osteomyelitis and to a lesser extent, smoking history but nevertheless the main risk factor for nonunion was shown to be diabetes mellitus (7). In this study, there was a 50% fusion rate however the remaining cohort had a 70% successful radiographic fusion if the patients with underlying diabetes were excluded from the analysis. Earlier studies done by Hopgood et al. (6) revealed fusion rates of up to 74% however, patients with extensive destruction of the talus had higher failure rates.

Functional scores (using SF-12 scores) done by a study (7) revealed that there was no significant difference between a subgroup of patients who developed a clinically stable pseudoarthrosis from those of the fused patients. This implies that a nonunion of a femoral head allograft tibiototalcalcaneal arthrodesis may not lead to a complete clinical failure and that 44% of nonunion did not require additional intervention (7).

Many authors however state that there are different criteria for success in diabetic patients especially those with neuropathy from those nondiabetic patients

(6). Radiographic nonunion may not be an indicator towards the success of surgery and a painless stable pseudoarthrosis that corrects deformity, allows weight-bearing, and maintains a healthy soft tissue envelope are indicators of clinical success.

Conclusion

Charcot's arthropathy is a complex disease leading to severe ankle and foot deformities causing severe debilitation to the patient. For limb salvage surgery, ankle fusion may be fraught with complications as a result of uncontrolled comorbidities. An adequate control of comorbidities will result in good percentage (> 50%) of patients attaining fusion with a good functional score. In cases with extensive bone lost, use of an allograft bone block remains a significant option and patients who undergo surgery tend to fare better despite nonunion.

Acknowledgement

The authors would like to thank the Head of Department of Orthopaedic and Traumatology, Faculty of Medicine, National University of Malaysia, Associate Professor Dr Jamari Sapuan for his permission to publish this case report.

Informed consent

Written informed consent was obtained from the patient for publication of this case report and the accompanying images.

Funding

This work received no specific grant from any agency.

Competing interests

The authors have no conflicts of interest to declare.

References

1. Siebachmeyer M, Boddu K, Bilal A, Hester TW, Hardwick T, Fox TP, *et al.* Outcome of one-stage correction of deformities of the ankle and hindfoot and fusion in Charcot neuroarthropathy using a retrograde intramedullary hindfoot arthrodesis nail. *Bone Joint J.* 2015;97-B(1):76-82.
2. Zakariah NA, Bajuri MY, Hassan R, Ismail Z, Md Mansor M, Othman H, *et al.* Is Procalcitonin more superior to hs-CRP in the diagnosis of infection in diabetic foot ulcer? *Malays J Pathol.* 2020;42(1):77-84.
3. Goh TC, Bajuri MY, Nadarajah CS, Abdul Rashid AH, Baharuddin S, Zamri KS. Clinical and bacteriological profile of diabetic foot infections in a tertiary care. *J Foot Ankle Res.* 2020;13(1):36.
4. Acosta R, Ushiba J, Cracchiolo A 3rd. The results of a primary and staged pantalar arthrodesis and tibiototalcalcaneal arthrodesis in adult patients. *Foot Ankle Int.* 2000;21(3):182-94.

5. Alfahd U, Roth SE, Stephen D, Whyne CM. Biomechanical comparison of intramedullary nail and blade plate fixation for tibiotalocalcaneal arthrodesis. *J Orthop Trauma*. 2005;19(10):703-8.
6. Hopgood P, Kumar R, Wood PL. Ankle arthrodesis for failed total ankle replacement. *J Bone Joint Surg Br*. 2006;88(8):1032-8.
7. Jeng CL, Campbell JT, Tang EY, Cerrato RA, Myerson MS. Tibiotalocalcaneal arthrodesis with bulk femoral head allograft for salvage of large defects in the ankle. *Foot Ankle Int*. 2013;34(9):1256-66.