

THE CUBITAL TUNNEL SYNDROME CAUSED BY MULTIPLE GANGLION CYSTS-A CASE REPORT

Ahmed Suparno BM¹, Lai Ho YK¹, You MS¹, and Wing YF².

¹Department of Orthopaedics, Advanced Medical and Dental Institute, Universiti Sains Malaysia, Kepala Batas, Penang, Malaysia

²Department of Orthopaedics, Hong Kong University, Hong Kong

Correspondence:

Dr. Ahmed Suparno Bahar Moni
Medical Lecturer, Orthopaedic Surgery,
Advanced Medical and Dental Institute,
Universiti Sains Malaysia,
Bertam, Kepala Batas,
13200 Penang, Malaysia
Phone number: +60175541823
Email: suparno1978@gmail.com

ABSTRACT

Cubital tunnel syndrome (CuTS) is the second most common nerve compression neuropathy in the upper extremity. Intra-neural ganglion cyst (IGC) within the ulnar nerve around the elbow, might present as CuTS. A 51-year-old Chinese man presented with paresthesia at the ulnar two digits of the left hand for one year. He was clinically diagnosed as severe CuTS. Nerve conduction study revealed marked axonal damage of the left ulnar nerve and ultrasonography showed a mass along the ulnar nerve, three centimetres proximal to the medial epicondyle, which was highly suggestive of Schwannoma. The mass was explored by a longitudinal incision. Intraoperatively, multiple cystic lesions were found within the epineurium of the ulnar nerve. Communication was seen between the elbow joint and the cyst. Swellings were partially excised under microscope. Decompression or partial excision of the cyst along with ligation of the articular branch should be the treatment of choice to prevent recurrence in case of IGC.

Keywords: *Intra-neural Ganglion Cyst, Cubital Tunnel Syndrome, Ulnar Nerve, Articular Branch*

Introduction

Cubital tunnel syndrome (CuTS) is the most common form of entrapment neuropathy of the ulnar nerve and the second most common nerve compression syndrome in the upper extremity (1). Common sites of ulnar nerve compression around the elbow are the arcade of Struthers, the medial intermuscular septum, the medial epicondyle, the cubital tunnel and the deep flexor pronator aponeurosis (2). Soft tissue masses like intra-neural or extra-neural ganglion, synovial chondromatosis, hemangioma, venous thrombosis, giant cell tumour of tendon sheaths, etc., could compress the ulnar nerve around the elbow and present similarly as CuTS.

Intra-neural ganglion cysts (IGC) are rare, mucinous, non-neoplastic lesions of the peripheral nerves that arise from the epineurium. Previously, many investigators supported the *de novo* (degenerative) theory of the formation of IGC. According to this theory, formation of IGC is the

result of mucoid degeneration of fibrotic tissue after repetitive micro-trauma (3). But it did not explain all the cases satisfactorily. A newer unifying articular (synovial) theory, proposed by Spinner et al, described the detail pathophysiological basis of the formation of IGC (3). Most of the investigators have accepted this new theory of IGC formation.

On the contrary, extra neural ganglion cysts (EGC) are relatively common mucinous cysts, present outside of the epineurium of the peripheral nerves, and connected to the nearby joint through the capsular tear (4). They are located separately from the articular branch of the nerve (4).

We are reporting a case of high ulnar nerve lesion, which was diagnosed clinically, and confirmed by the electro-diagnostic study as CuTS. Ultrasonographic (USG) findings of the case were consistent with ulnar nerve tumor. And, finally the case was diagnosed per-operatively as multiple IGC of the ulnar nerve.

Case report

A 51-year-old Chinese man presented to our outpatient clinic with tingling and numbness at the ulnar two digits of the left hand for around one year. On examination, there was clawing at the ulnar two digits (Figure 1) of the left hand, hypothenar muscles were wasted, and sensation was markedly reduced over the area. Card test and Froment's sign were found positive, Tinel's sign and compression of the nerve at the cubital tunnel were also found positive. Clinically, he was diagnosed as a case of severe CuTS and was advised for the USG of the ulnar nerve around the elbow and electrodiagnostic study. Nerve conduction study (NCS) of the left upper limb revealed that the sensory and motor conduction of the left ulnar nerve was not elicitable and there was marked axonal damage of the left ulnar nerve. USG findings showed a mass, along the ulnar nerve, at about three centimetres proximal to the medial epicondyle of the left elbow. The mass was cystic in nature with increased vascularity and displaced the nerve fibres laterally. The radiologist commented that the mass was highly suggestive of Schwannoma (Figure 2).

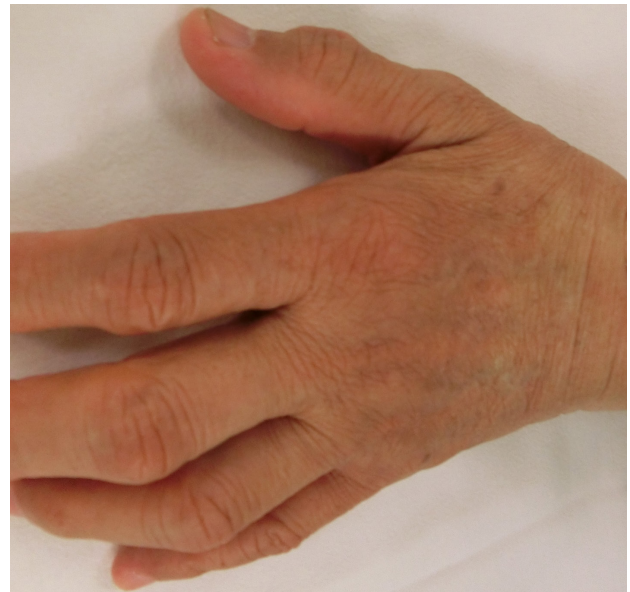

Figure 1: Ulnar clawing was noted at the left hand, preoperatively

After obtaining informed consent, the patient was scheduled for the elective surgery under general anesthesia. A single dose of antibiotic was given prior to the induction of anaesthesia. The patient was placed into the supine position. His left hand was kept perpendicularly on a hand table and a high above-elbow sterile tourniquet was fastened at the left hand. A 10 cm longitudinal incision was made at medial aspect of the arm extending over the cubital tunnel. The ulnar nerve was identified under loupe dissection (Figure 3). Multiple cystic lesions were found within the epineurium of the ulnar nerve. Unhealthy fascicles were found inside the lesions. There was communication between the elbow joint and the cysts. Gelatinous materials were noted coming out from the elbow joint. Cysts were dissected under the microscope. They were entirely filled with the mucinous fluid. Cystic swellings were diagnosed as IGC of the ulnar nerve, originating from the elbow joint (Figure 4). Generalized thickening of the ulnar nerve was also noted around the elbow.

Swellings were partially excised and sent for the histopathology. Connection between the cysts and the elbow joint was ligated. The ulnar nerve was completely released at the cubital tunnel. As it was found stable in its position with elbow flexion and extension, anterior transposition of the ulnar nerve was not done. The wound was closed in layers keeping a deep drain.

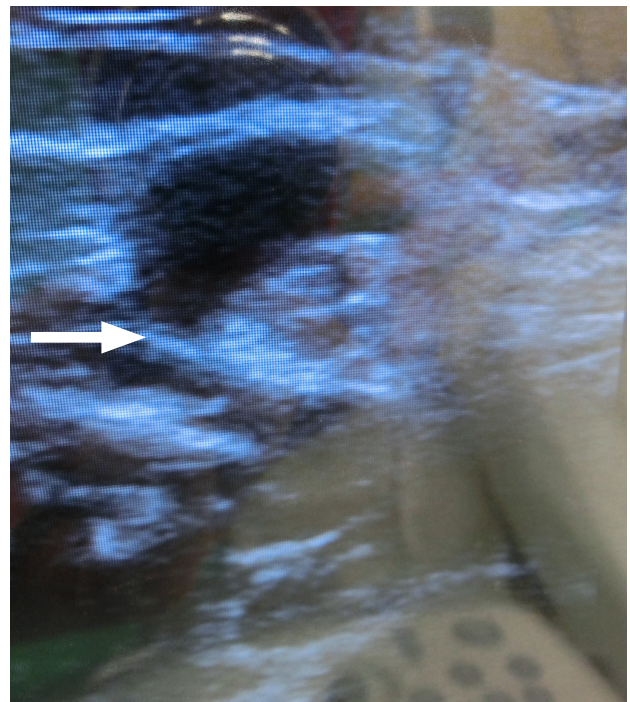


Figure 2: USG finding of the swelling in the left ulnar nerve above the cubital fossa

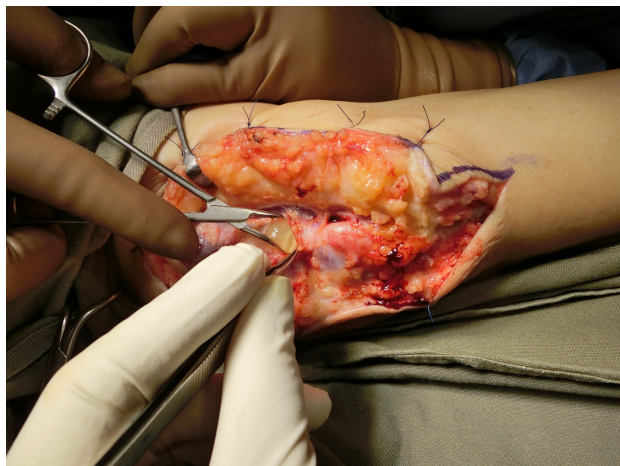

Figure 3: Incision was made on the epineurium of the ulnar nerve over the swelling; gelatinous material was found inside

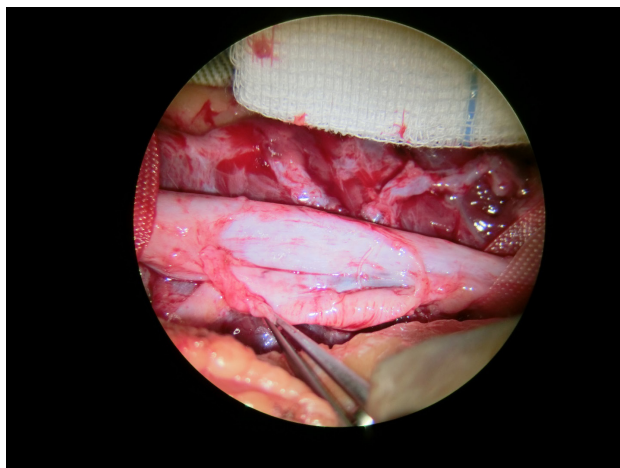


Figure 4: Another cystic swelling was noted under microscopic dissection

The histopathology result was consistent with the multicystic ganglion cyst. At 6 weeks, the wound was healed adequately and patient was sent for physiotherapy. The patient was evaluated at follow-up clinic at the third, sixth, 12th and 24th month post-surgery. An MRI was done after seven months of the surgery. No residual or recurrent cystic lesion was detected along the course of the ulnar nerve. The ulnar nerve was identified in anatomic alignment and was unremarkable. On follow up, there was gradual improvement of the numbness and intrinsic strength of the left hand, and no recurrence of the cyst was noted clinically.

Discussion

The cases of multiple IGC within the ulnar nerve around the elbow, which presented as CuTS, are rarely reported in the literature. They usually are diagnosed per-operatively, as most centres routinely do only NCS in cases of clinically-

diagnosed CuTS. The reported prevalence of CuTS due to elbow cyst varies from six to 10% in different literature (4). USG or MRI could diagnose IGC preoperatively. High-resolution imaging (magnetic resonance arthrography) and post-processing three-dimensional reconstruction and new three-dimensional fast-spin echo-extended echo train MRI sequence provides better visualization of IGC along with their articular connection (2, 3). In our case, a cystic lesion was identified preoperatively by USG. However, USG finding was more consistent with nerve tumor, schwannoma, and we did not advise for the preoperative MRI in this case.

IGC are commonly seen in the elderly, male, and manual workers (4). Our patient also belonged to the same group.

IGCs are mostly documented in lower limb nerves. The most commonly affected nerve is the common peroneal and the commonest site is the fibular neck region (5). It is extremely rare in upper extremities. However, in the upper limb, IGC are documented mostly in the ulnar nerve.

The pathogenesis of the formation of IGC remains controversial until today. A variety of theories have been proposed regarding its formation. Previously, many investigators supported the older *de novo* (degenerative) theory of formation. However, currently the latest unifying articular (synovial) theory has gained popularity by most researchers (3). According to this theory, IGC arises from the neighboring synovial joint. An articular branch takes the principal role in its formation. The cyst fluid follows the low-pressure pathway and runs along the articular branch in the direction of the pressure fluxes from the synovial joints (2). In most of the reported cases, communication with the neighboring joint was initially missed during the first surgery, and detected post-operatively either in follow-up MRI in cases of recurrence or at revision surgery. In our case, we were able to find out the communication between the cyst and the elbow joint under microscopic dissection, per-operatively.

Same as the pathogenesis, treatment of IGC also varies according to the surgeons' preferences. In case of asymptomatic IGC, most surgeons follow the conservative management protocol by regular follow-up. However, symptomatic IGC of the peripheral nerve requires proper attention. In such cases, some surgeons prefer the least invasive, percutaneous aspiration. Some go for the most aggressive method, complete resection of the diseased part of the nerve and end to end repair or reconstruction of the diseased nerve with nerve graft or even nerve transfer (2). After acceptance of the unifying articular theory of pathogenesis, the current treatment plan adds identification and transection or ligation of the pathological articular branch connection between IGC and the neighboring joint, along with cyst excision, to prevent recurrence (4). In our case, we found the communicating articular branch between the elbow joint and IGC per-operatively, and ligated it completely, along with the partial cyst excision. An MRI was done seven months post-surgery, which showed no residual cyst or recurrence.

However, literature reviews do not show whether cyst decompression or complete excision is the better treatment option for IGC in terms of long-term functional recovery of the nerve. Along with the isolation and ligation of the articular branch, decompression of the cyst by incision and evacuation of the mucinous fluid is now widely practiced than the more radical complete excision, to avoid iatrogenic nerve injury. We also routinely practice either decompression or partial excision of the cyst, along with the ligation or transection of the articular branch, for the management of IGC.

Conclusion

Multiple IGC within the ulnar nerve is a rare condition. Either decompression or partial excision of the cyst, along with ligation or complete transection of the articular branch could be the treatment of choice to prevent recurrence and get optimal functional recovery.

Acknowledgement

The authors would like to acknowledge Ms Doris Lau, from the office of Orthopaedic surgery, Faculty of Medicine, The University of Hong Kong.

References

1. Li YP, Lao J. The cubital tunnel syndrome caused by the two synovial cysts. *J Plast Reconstr Aesthet Surg.* 2012;65(6):827-9.
2. Ozturk U, Salduz A, Demirel M, Pehlivanoglu T, Sivacioglu S. Intraneural ganglion cyst of the ulnar nerve in an unusual location: A case report. *Int J Surg Case Rep.* 2017;31:61-4.
3. Spinner R J, Harish S, Amrami K K. An historical perspective on ulnar intraneural ganglion cysts and their joint origins. *Hand (N. Y.)* 2014;9(3):395–8.
4. Chang WK, Li YP, Zhang DF, Liang BS. The cubital tunnel syndrome caused by the intraneural or extraneural ganglion cysts: Case report and review of the literature. *J Plast Reconstr Aesthet Surg.* 2017;70(10):1404-8.
5. Chick G, Alnot JY, Silbermann-Hoffman O. Intraneural muroid pseudocysts: a report of ten cases. *J Bone Joint Surg Br.* 2001;83(7):1020-2.