

FERRET : THE ANIMAL OF CHOICE IN DENTAL EXPERIMENTS

Alani AH, Razak AAA. *Ferret: the animal of choice in dental experiments.* *Annal Dent Univ Malaya* 1996; 3: 39-42

SUMMARY

The canine teeth of the mature ferret have closed apices. They are easily accessible for operating purposes and are sufficiently large, allowing conventional cavity preparation techniques to be prepared using ordinary dental instruments. Handling of the ferret is relatively easy since it becomes quite tame after a period of time. The body weight in male is greater and the teeth larger than those of the female. The cost of purchase and maintenance of the ferret is also inexpensive. For all these reasons, the ferret male is animal of choice in dental experiments.

Key Words: Dental pulp, Ferret, Histology.

INTRODUCTION :

Three possible research methods exist for studying the effects of restorative materials upon the dental pulp. These are: (i) the use of human teeth, (ii) the use of experimental animals and (iii) tissue culture.

The ideal method for examining the effects of restorative materials upon the pulp lies in human studies using teeth destined for non-urgent extraction, for example teeth extracted for orthodontic, prosthetic or for other reasons (e.g. impacted 3rd molars).

It is difficult, however, to collect a sufficient quantity of human material at definitive time intervals after restoration.

Cell culture or tissue culture tests have been used by some workers for the screening of restorative materials for possible toxicity (1, 2). Tissue culture tests are easily influenced by various factors. To obtain constant results, it is important to use the same standard cell, the same number of inoculate cells, the same pre-culture time, same components, same amount of culture medium and the same active surface of the test piece in its area and roughness (3). Tissue culture are effective in the selection of components to make new products before usage test and clinical trials, and also for quality control after production.

The dental pulp is, however, a specialised tissue consisting of fibroblasts, histiocytes, undifferentiated mesenchymal cells, blood vessels and nerve tissue. It is bordered by the layer of odontoblast cells whose processes pass into the dentinal tubules. All these features relate to the effect of toxicity of restorative materials. It is not possible, therefore, for tissue culture techniques to imitate accurately this unique hard to soft tissue relationship.

EXPERIMENTAL ANIMALS

Animal experiments have been used for many years to study dental pulp reaction. For example in 1922, Rebel (4), studied the effect of pulp capping procedures on dogs and cats. Since then various animals including rats, rodents, monkeys, dogs, cats and ferrets have been used to examine various aspects of pulp healing.

* Adil Hamed Alani BDS, HDD, PhD.
Abdul Aziz Abdul Razak BDS, MSc, PhD.

Department of Conservative Dentistry
Faculty of Dentistry
University of Malaya
50603 Kuala Lumpur
Malaysia

* Corresponding author

A number of factors must be considered when choosing the animal for such investigations. These are:

1. The morphology and histology should bear a close resemblance to human teeth.
2. The size of the tooth and pulp should be large enough to allow preparation of a reasonable size cavity.
3. The accessibility of the experimental teeth should be sufficient for use of instruments and techniques readily available in clinical use.
4. The size and weight of the experimental animal should be convenient for handling and housing.
5. The cost of purchase and maintenance of the animal should not be excessively high.

The monkey is the animal model which is closest to the human in respect of tooth morphology, histology and tissue reaction. It has been used to investigate periodontal disease (5), to study histology of the dental pulp (6), to study pulpal reaction to restorative materials (7, 8) and for endodontic research (9). It is, however, extremely expensive, both to purchase and in its upkeep, and the problem of inter-species transmission of disease between the human and the monkey is one that cannot be ignored.

The dog is another experimental animal which is used widely for dental research. It has been used to study pulpal reaction to restorative material (10), for endodontic research (11) and to study periapical lesions (12). Dogs, however, are also expensive to purchase, house and maintain.

The cat was the animal used to study the effects of filling materials on the dental pulp and periapical tissues (13, 14). This is also an expensive laboratory animal.

The rat is another experimental model whose molars have been used to evaluate the response of the exposed pulp to the toxicity of restorative materials (15,16). Rodents, however, have continuously erupting incisors which do not have closed apices and it is possible, therefore, that the response of the dental pulp to irritant stimuli will be different from that in humans. In addition, teeth in rats are extremely small and are considered unsuitable for cavity preparation.

The ferret has been investigated as an experimental animal for dental research (17,18,19). It has been used for periodontal research (20), alveolar bone metabolism (21) and for caries research (17). The pulpal response to dental materials has been widely investigated using the



Fig.1 Ferret animal.

ferret (22,23,24). It has also been used more recently for endodontic research (25).

THE FERRET

The ferret (order carnivora, Super-family Canoidea, Family Mustelidae) is a domesticated albino breed derived from the wild polecat (*Putorius faetidus*) and has a yellowish white, brown fur and reddish pink eyes (Fig. 1).

Berkovitz and Silverstone (17) have described the morphological features of the ferret dentition. The dental formula for the permanent dentition of the ferret is:

$$I_{\frac{3}{3}} \quad C_{\frac{1}{1}} \quad P_{\frac{3}{3}} \quad M_{\frac{1}{2}}$$

The carnassial tooth in the upper jaw is P4 and in the lower jaw is M1.

The canines are the only teeth used in dental experiments as the other single-rooted teeth are extremely small. The canines have a recurved crown. Fig. 2 shows the large canines and small incisors of the ferret.

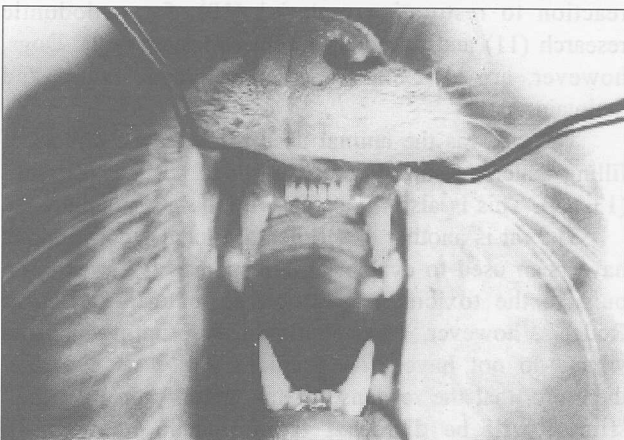


Fig. 2 Large permanent canines and small incisors of the ferret.

In the upper jaw, the canine represents a crown approximately 8 mm in height, measured from the incisal tip to the gingival margin, 3 mm in bucco-lingual dimension and approximately 3.5 mm mesio-distally measured at the gingival level. The root is approximately 10.5 mm long. The lower canine measures approximately 7 mm in height, 2.75 mm bucco-lingually and 3 mm in a mesio-distal direction at the gingival margin level. It also possesses a small cingulum on the lingual aspect of the recurved crown. The root of the lower canine is approximately 9.5 mm long.

The date of eruption for both upper and lower permanent canines is approximately 50 days after birth. The ferret maintains a steady body weight at thirteen months when its dentition is mature.

COMPARISON OF THE HUMAN DENTAL PULP AND THAT OF THE FERRET

The matter of inter-species comparison raises the much wider question, "what is the relevance of animal studies to humans?" As far as these experiments are concerned, given the similarities in pulpal anatomy and histology between human and ferrets, it is believed that the results can give a general indication of the likely response in humans to the materials tested. It must be conceded, however, that apart from the difference in tissue response, the size of the restorations and the masticatory forces to which they are subjected can be quite different in ferrets when compared to human. The size of restoration and masticatory load are factors both likely to influence the marginal integrity of dental restorations.

The ferret dental pulp appears to differ from the human pulp in two main features:

Firstly, the presence of cell-free and cell-rich zones in the sub-odontoblastic region of the human indicates a greater degree of cellular organisation when compared with the ferret pulp which has no such zones.

The significance of the cell-free zone was studied by Gotjamanos (6) when he investigated the cellular organisation in the subodontoblastic region in adult rat and deciduous monkey teeth. He suggested that the presence of nerve fibers in cell-free zones formed an important link in the sensory mechanism operating between dentine and pulp. The absence of cell-free zones in the rat pulp and its presence in the monkey and in humans, may be indicative of a less specialised sensory apparatus in the rat tooth and could, therefore, be of evolutionary significance. In the same way, the absence of the cell-free zone in the subodontoblastic region in the ferret tooth may indicate a less specialised sensory apparatus.

Al-Rubayi (18) pointed out that the cell-free zone may be an artefact because it is not seen in developing teeth and its presence is said to vary with histological treatment. He clarified, however, that cell-free zones and cell-rich zones in the coronal pulp are not histological artefacts but represent distinct microanatomical features of the human pulp.

The second main difference between the ferret and



Fig. 3 Histological appearance of the ferret dental pulp.
H & E stain - Original magnification x 40.

human dental pulp is the regular occurrence of vessel dilatation in the ferret which suggest that the tooth has been subjected to some sort of trauma. This is probably due to the ferret using the canines to gnaw the bars of the cage resulting in vascular changes of the pulp. However, others (26) have concluded from their study that excessive occlusal force over a short period of time (0-7 months), did not cause pulpal changes in the tooth of the rat and it is possible, therefore, that vessel dilatation may be a normal morphological feature in the pulp of the ferret. Further experiments conducted by Landay, as cited by Al-Rubayi (18), indicated that heavy forces applied to the rat molar by cementing a metal post into the molar tooth, had brought degeneration and inflammatory changes in the pulp of the opposing molar after 7 months. The odontoblasts underwent atrophic changes and scattered chronic inflammatory changes began to appear in the pulp. This would add weight to the suggestion that the vascular dilatation seen in the ferret is the result of gnawing action.

HISTOLOGY OF THE DENTAL PULP IN THE FERRET

Alani (24) described the histology of the dental pulp in the ferret. He stated that examination of haematoxylin and eosin stained sections of canine tooth specimens reveal a basophilic darkly stained dentine and an eosinophilic

pre-dentine. A palisading layer of odontoblasts several cells thick is seen all round the pulp periphery underlying the pre-dentine. An apparent pulpo-dentine membrane forms the junction between the periphery of the pulp and pre-dentine. The odontoblast is a highly differentiated cell in the pulp. In the coronal portion of the pulp, they are columnar in shape. They have elongated nuclei situated at the proximal end of the cells while the distal end of the cells forms the odontoblast processes which penetrate the pre-dentine. The odontoblasts elaborate regular dentine with regular dentinal tubules. Towards the root, the odontoblasts cells seem to reduce in number and assume a cuboidal form with ovoid nuclei. This is observed at about the middle portion of the root. The odontoblasts towards the apical third of the root lies in a single chain of flattened cells resembling fibroblasts and lying parallel to the pre-dentine. Directly beneath the odontoblasts, and throughout the pulp, cellular elements are found to be evenly distributed, although a slight cellular increase is observed in the subodontoblastic region in the coronal part of the pulp.

Blood vessel dilatation is a consistent feature, with some showing stasis and brown pigment formation. Also a slight pavingmenting of white cells is seen with occasional cells actually outside the vessels. This is more pronounced in the incisal region of the pulp. The basic cells of the pulp are fibroblasts and are similar to connective tissue fibroblasts found elsewhere in the body. They form a syncytium of spindle-shaped cells. Nerve trunks run in the middle of the pulp and parallel to the long axis of the tooth, usually beside blood vessels. Collagen can be seen in abundance at the apical region and thick bundles of the collagen can also be seen accompanying the nerve trunks. However, at the subodontoblast region, the amount of collagenous material decreases and subodontoblastically where the Von Korff fibres are seen in abundance. These fibres form the fibrillar framework of dentine and pass between the odontoblasts and fan out into the unmineralized dentine or pre-dentine in a delicate meshwork. Also seen are histiocytes and undifferentiated mesenchymal cells lying close to capillaries in the pulp.

REFERENCES

1. Browne RM. In vitro assessment of toxicity of dental materials - does it have a role? Abstract presented at the conference in vitro assessment of the biocompatibility of dental materials. *Int Endod J* 1987; 20: 242.
2. Hensten-Petersen A. Comparison of the methods available for assessing cytotoxicity. Abstract presented at the conference in vitro assessment of the biocompatibility of dental materials. *Int Endod J* 1987; 20: 244.
3. Kawahara H. Cell growth and colony-forming rate calculated by microcomputer. Abstract presented at the conference in vitro assessment of the biocompatibility of dental materials. *Int Endod J* 1987; 20: 245.
4. Rebel HH. *Über die ausheilung der freigeleiteten pulpa.* *Dtschzahnheilk Votr H* 1922; 55:1-83.
5. Goldmand HM. Periodontosis in the spider monkey - A preliminary report. *J Periodontol* 1947; 18: 34-40.
6. Gotjamanos T. Cellular organisation in the sub-odontoblastic zone of the dental pulp. I. A study of cell-free and cell-rich layers in pulps of adult rat and deciduous monkey teeth. *Arch Oral Biol* 1969; 14: 1007-10.

7. Safer DS, Avery JK and Cox CF. Histopathologic evaluation of the effects of new polycarboxylate cements on monkey pulps. *Oral Surg* 1972; 33: 966-75.
8. Van Leeuwen MJ, Dogon IL and Heeley J. A histological study of two visible light-cured esters of Bis-GMA. *J Dent Res* 1985; 64: 222, Abstr No. 425.
9. Dumsha T and Hovland EJ. Evaluation of long-term calcium hydroxide treatment in avulsed teeth - an in vivo study. *Int Endod J* 1995; 28: 7-11.
10. Brannstrom M and Nyborg H. Dentinal and pulpal response. IV. pulp reaction to zinc oxyphosphate cement - a morphologic study on dog and man. *Odont Revy* 1960; 11: 37-50.
11. Lantz B and Persson PA. Periodontal tissue reactions after root perforation in dog's teeth. A histologic study. *Odontol Tinskr* 1967; 75: 209-37.
12. Pitt-Ford TR. The radiographic detection of periapical lesions in dogs. *Oral Surg* 1984; 57: 662-7.
13. Rowe AHR. A study of the effects of various filling materials on the dental pulp and periapical tissues. MDSc Thesis, University of London, 1965.
14. Oswald RJ and Friedman CE. Periapical response to dentine fillings. A pilot study. *Oral Surg* 1980; 49: 344-55.
15. Watts A. Bacterial contamination and the toxicity of silicate and zinc phosphate cements. *Br Dent J* 1979; 146: 7-13.
16. Paterson RC and Watts A. Toxicity to the pulp of a glass-ionomer cement. *Br Dent J* 1987; 162: 110-2.
17. Berkovitz BKB and Silverstone LM. The dentition of the albino ferret. *Caries Res* 1969; 3: 369-376.
18. Al-Rubayi AA. Studies on pulp in the ferret. PhD Thesis, University of Birmingham, England, 1971.
19. Berkovitz BKB. Tooth development in the albino ferret (*Mustela putorius*) with special reference to the permanent caranassial. *Arch Oral Biol.* 1973; 18: 465-71.
20. King JH. Experimental investigations of paradontal diseases. I. The significance of blood supply in gingival health and disease in ferrets. *Br Dent J* 1944; 77: 213-21.
21. Rogers HJ and Weidman SM. Metabolism of alveolar bone. *Br Dent J* 1951; 90: 7-10.
22. Tobias RS, Browne RM, Plant CG. and Ingram DV. Pulp response to a glass-ionomer cement. *Br Dent J* 1978; 144: 345-350.
23. Tays MJ, Tobias RS and Bovis SC. An apparatus for the preparation of cavities in canine teeth of ferrets. *J Oral Rehabil* 1980; 7: 21-26.
24. Alani AH. The influence of dentine bonding agents upon the microleakage associated with composite resin restorations and their effects upon the dental pulp. PhD Thesis, University of Dundee, Scotland, 1990.
25. Saunders EM. In vitro and in vivo investigations into root canal obturation using thermally softened gutta-percha techniques. PhD Thesis, University of Dundee, Scotland, 1988.
26. Landay MA, Naznimov H and Seltzer S. The effects of excessive occlusal force on the pulp. *J Periodontol* 1970; 41: 3-11.