



Vertical Play of Straight Wire Appliance Aids Correction of Gummy Smile and Bimaxillary Incisor Proclination with Mini Implant Anchorage

Mohd Zambri MM¹, Wan Nurazreena WH²

¹ Orthodontic Unit, Klinik Pergigian Cahaya Suria, Bangunan Cahaya Suria, Jalan Tun Perak, 50050 Kuala Lumpur, Malaysia. zambrimakbul@gmail.com

² Department of Paediatric Dentistry and Orthodontics & Clinical Craniofacial Dentistry Research Group, Faculty of Dentistry, University of Malaya, Kuala Lumpur, Malaysia. wannurazreena@um.edu.my

ABSTRACT

This report aimed to describe an effective biomechanics to control the upper incisors inclination during the correction of gummy smile with bimaxillary proclinations. A 14-year-old female presented with a Class II division I incisor relationship complicated with bimaxillary proclination on a Class 2 skeletal base. The lips were incompetent, showing 7 mm of upper incisors at rest and 5mm maxillary gingival display on smiling with normal upper lip length. Treatment involved extraction of all first permanent premolars followed by upper and lower fixed appliances. Intrusion of the upper incisors with controlled labial crown torque was accomplished with mini-implant anchorage placed bilaterally on the infrazygomatic crests with the retraction forces above the centre of resistance using 0.019x0.025-in stainless steel archwire in 0.022-in slot. The 0.019x0.025-in stainless steel archwire in 0.022-in slot provided the vertical play to favour lingual crown tipping despite having forces above the centre of resistance for concurrent anterior segment intrusion.

Keywords: Orthodontic mini-implant; early treatment; anchorage; diagnosis and treatment planning; intrusion mechanics, en-mass retraction

INTRODUCTION

The smile aesthetic is one of the key measures of the success of a treatment. A common chief complaint leading to a request for orthodontic treatment is excessive display of contiguous band gingivae on posed smiling, also known as a gummy smile. Although some amount of gingival display is associated with a youthful appearance (1), too much gingival display is often considered unattractive. Gingival display of up to 25% of the upper incisor crown height or up to 3mm is considered acceptable before aesthetics is considered compromised (2).

The more exposed the gingival display, the more complicated the treatment options to address the unaesthetic smile line: from orthodontic intrusion to combination involving orthodontics, periodontics treatment and/or restorative dentistry to orthognathic

surgery (3). Orthodontic camouflage to correct the gummy smile can be further complicated if extraction is necessary, for example, in cases that require overjet reduction or reduction of the inclination of the upper anterior teeth. Retraction of the upper anterior segment, even with the largest dimension of 0.019x0.025-in stainless steel archwire on a 0.022-in slot, inevitably causes retroclination of the incisors due to the 5-10° of play between the archwire and bracket slot interface (4). The retroclined incisors result in additional gingival display, making the gummy smile more obvious. Cases with bimaxillary incisor proclination often require extraction of all 4 first premolars with maximum retraction of the incisor teeth to address the dentoalveolar flaring of the anterior teeth and to reduce the protrusion of the lips and convexity of the face. En-masse retraction

favours reduction of the bimaxillary proclination but further worsens the aesthetic of the gummy smile.

Mini-implants may be considered as an effective anchorage device during en-masse retraction of the anterior teeth. In past reports (5-7), treatment involved placement of mini-implants bilaterally at the mucogingival junction between the maxillary first molars and second premolars. The maxillary anterior teeth were en-masse retracted using 150g force from the mini-implant to the standard height crimpable hooks distal to the lateral incisors, which were vertically close to the cemento-enamel junction of the incisors. Upadhyay *et al.* (2008) found that such mechanics resulted in a large retraction force and a smaller intrusive force. The mechanics were also found to be effective in preventing extrusion of the molars (5, 7). Such mechanics can prevent worsening of a gummy smile but would not efficiently reduce the vertical maxillary excess display.

By applying the hypothesis of vertical play in the bracket-archwire slot (8), this case report discusses the mini-implant mechanics to induce maximum en-masse retraction and optimum intrusion of the maxillary anterior teeth to reduce the gummy smile, incisor proclination and overjet. This improved the smile aesthetics of our adolescent patient.

Diagnosis and Aetiology

The patient was a 14-year-old, female, with a chief complaint of gummy smile and protruding upper

front teeth. She was in a good health and had no significant medical history.

Extra-orally she presented with a Class 2 skeletal base with an increased Frankfort-mandibular planes angle and increased lower facial height ratio. There was no obvious facial asymmetry. The lips were incompetent, showing 7mm of upper incisors at rest and 5mm maxillary gingival display on smiling with a normal upper lip length. The nasolabial angle was acute and the labiomento fold was shallow. Intraorally, examination revealed full permanent dentition with 3mm crowding in the upper and 4mm crowding in the lower arches. The maxilla and mandibular arch shapes were U-shaped and the upper and lower incisors were proclined. On occlusion, the incisor relationship was in a Class II division 1 relationship with an overjet of 7mm. The overbite as measured from the left central incisors was increased by 60% and complete to the teeth. The curve of Spee measured from the occlusal plane between the distal cusp of the lower second molar to the lower central incisal edge was 4mm, which indicated added space requirement (9). The buccal segments on the right and left sides were in Class I molar relationships and ½ unit Class II canine relationships. The upper centreline was 2mm to the right of the facial midline, and the lower centreline was coincident with the facial midline (Figure 1 and 2).

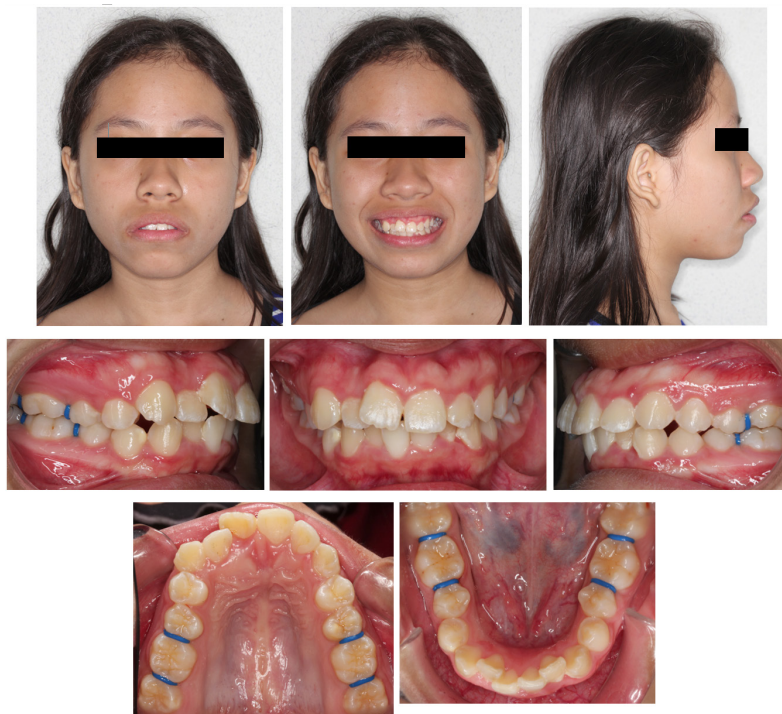

Figure 1: Pre-treatment facial and intraoral photographs

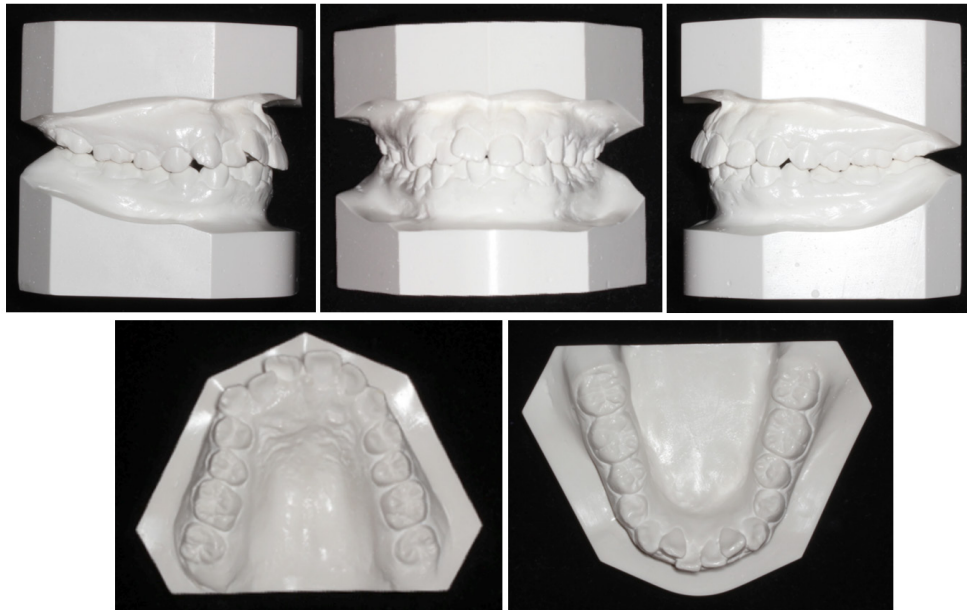

Figure 2: Pre-treatment study models

The pre-treatment panoramic radiograph (Figure 3) shows that the bone level was normal with all teeth present in the upper and lower arches. All third molars were in the developing stage. The lateral cephalometric radiograph (Figure 2) shows that the patient presented with a Class 2 skeletal base with an increased maxilla-mandibular planes angle; upper and lower incisors were proclined. The upper and

lower lips appeared protrusive from the E-plane by 3.5mm and 4.5mm, respectively. However, it should be noted that the lateral cephalometric radiograph was taken with the lips pursed and not in a rest position. The radiograph was not repeated due to the risk of ionizing radiation and in any case would not have influenced the treatment plan.

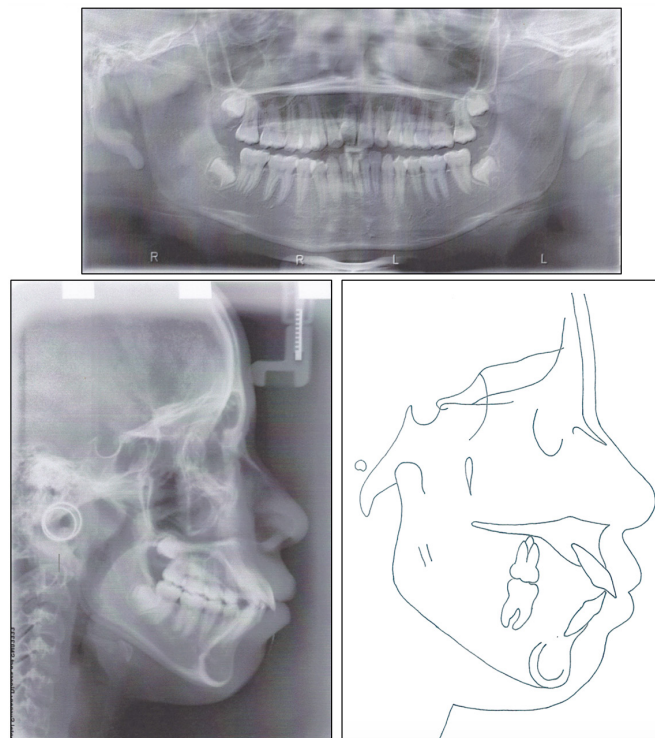


Figure 3: Pre-treatment panoramic radiograph and lateral cephalometric radiograph and tracing

The aetiology of the malocclusion was due to a Class 2 skeletal pattern, increased vertical proportion and backward growth of the mandible. Crowding was attributed to tooth-arch length discrepancy while the bimaxillary proclination was due to low lip muscle tone.

Treatment Objectives

Our objectives for this patient focused on these 6 objectives: (i) Secure optimum oral hygiene before starting orthodontic treatment; (ii) Ensure vertical control in the reduction of maxillary gingival display; (iii) Eliminate dental crowding; level and align the teeth; (iv) Retract upper and lower incisors in order to achieve lip competency; (v) Obtain ideal overbite and overjet and (vi) Achieve a mutually protective functional occlusion.

Treatment alternatives

The main problem for this patient was increased upper incisal show at rest and increased maxillary gingival display during smiling. Based on these problems, 3 options were proposed and related risks explained to her father.

1. The first option involved a combination of orthodontic treatment and orthognathic surgery but was recommended to commence after her growth had ceased. Orthognathic surgery by maxillary impaction is aimed to correct the anterior vertical maxillary excess and simultaneously correct the gummy smile.
2. The second option involved a J-hook headgear and fixed appliances. This would require insertion of a transpalatal arch followed by the extraction of all first premolars, with fixed appliances in combination with the use of a J-hook headgear. The J-hook headgear is primarily used to intrude and retract the upper incisors in order to correct the gummy smile. This option required excellent patient cooperation to wear the headgear and carried a risk of injury on the extra-oral soft tissue such as laceration or eye injury if the patient was not careful with the headgear.
3. The final option involved orthodontic camouflage. This involved placement of a transpalatal arch followed by the extraction of all first premolars. Fixed appliances in combination with mini-implant as an absolute anchorage were to be used to retract and intrude the upper incisors in order to correct the gummy smile.

After the discussion, the father did not want her to undergo orthognathic surgery and requested early treatment. The patient also refused to have headgear as a part of the treatment.

The treatment plan included the following: (i) Placement of transpalatal arch followed by the extraction of all first premolars; (ii) Upper and lower fixed appliances (0.022x0.028-in slot, MBT prescriptions); (iii) Placement of 2 mini-implants bilaterally for en-masse retraction; (iv) Finishing and detailing; (v) Upper and lower modified Hawley retainers. Verbal and written consent were taken from the patient and father for the agreeable treatment.

Treatment progress

Orthodontic treatment started in October 2014 and finished in May 2016. It took 17 months to achieve a good occlusion. Before extraction of all first premolars, the transpalatal arch was cemented. After extraction of all first premolars, pre-adjusted edgewise brackets (0.022x0.028-in, MBT prescription) were bonded to all the teeth except the second molars.

Upper and lower 0.012-in nickel titanium archwires were placed and treatment progressed up to 0.019x0.025-in stainless steel archwires. Initial alignment followed by levelling in the upper and lower arches was achieved in 4 months. Upper and lower 0.019x0.025-in stainless steel archwires were maintained for 2 months in order to fully express the torque.

Mini-implants (AbsoAnchor, Dentos Inc, Korea, 1.6mm diameter, 7.0mm length) were placed bilaterally at the infrazygomatic crest between the maxillary second premolar and first molar (10-11). In the upper arch, power arms (3M Unitek™ crimpable spiral hook) were placed on 0.019x0.025-in stainless steel archwires between upper lateral incisors and canines (12). En-masse retraction of the upper arch were done with elastic chains (150g) positioned at approximately 6mm height to the archwire, connecting the mini-implants to the power arms.

In the lower arch, 0.019x0.025-in stainless steel posted hook was used for en-masse retraction. Elastic chains (150g) were placed from the posted hook to lower first molars in order to retract lower arch (Figure 4).

After all the spaces closed, the lower second molars were bonded and aligned with 0.017x0.025-in nickel titanium archwire. The lower archwire progressed to a 0.019x0.025-in stainless steel archwire to further express the torque on the lower teeth. The upper arch was maintained with 0.019x0.025-in stainless steel archwire, and 0.012-in ligature wires were tied on the upper canines to

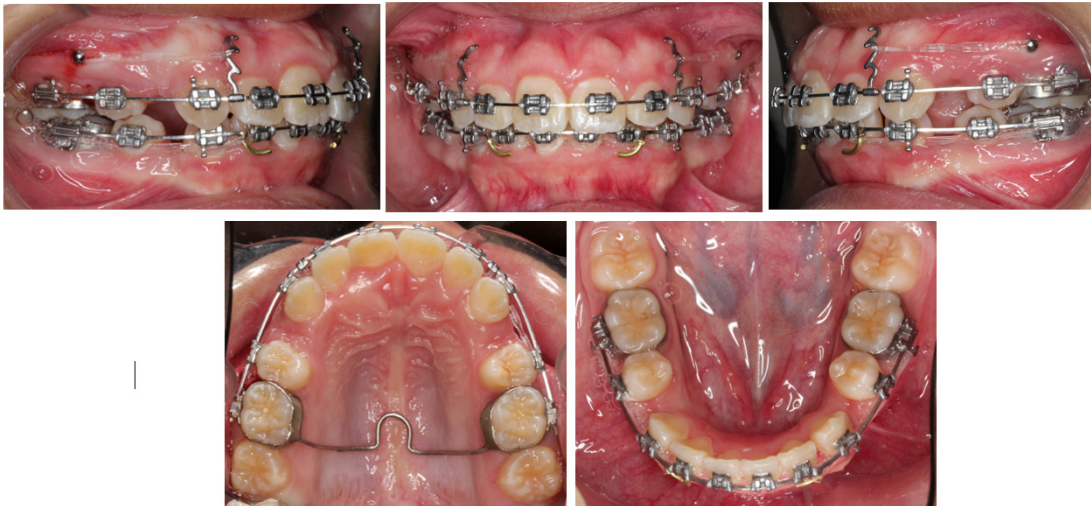


Figure 4: Middle treatment with the retraction of upper and lower arches on 0.019"X0.025" stainless steel archwires

the mini-implants to maintain the Class I canine relationship. Two months of finishing and detailing were done, the brackets were debonded and the patient was given the modified Hawley retainer. The patient was instructed to wear the retainers for 24 hours throughout 6 months and to continue wearing the retainers at night indefinitely.

Treatment results

Figures 5 to 8 show the final outcome of the case. There was significant improvement of the facial

profile due to retraction of upper and lower lips, as shown in the general superimposition (Figure 6). The upper and lower lips were retracted 1.5mm from the pre-treatment position. The retraction of upper and lower incisors was significant, simultaneously improving the position of maxilla and the mandible in relation to the cranial base due to the remodelling of A point and B point. Clockwise rotation of the mandible due to the extrusion of lower molars slightly increased the vertical dimensions by 1% increase in lower face height ratio.

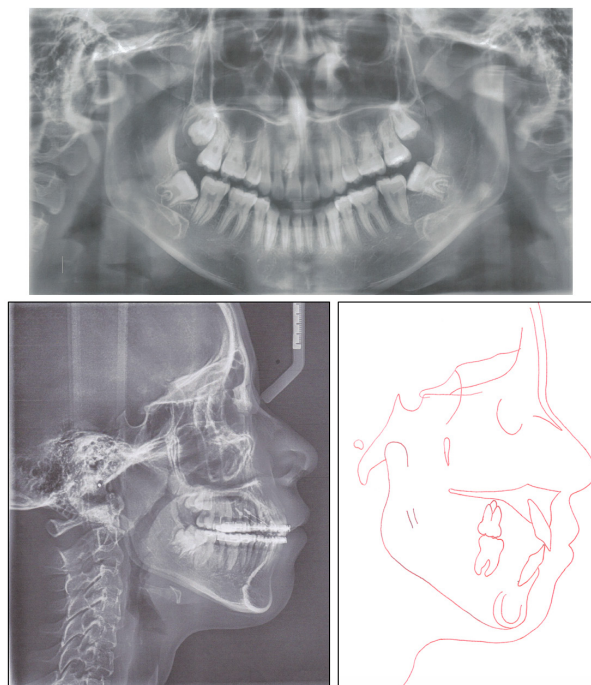


Figure 5: Post-treatment panoramic radiograph and lateral cephalometric radiograph and tracing

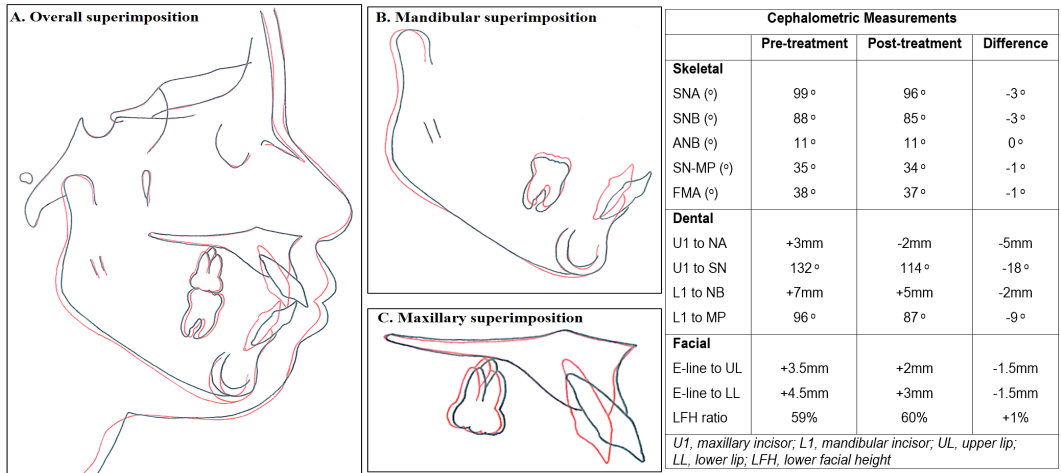


Figure 6: Cephalometric superimpositions and measurements

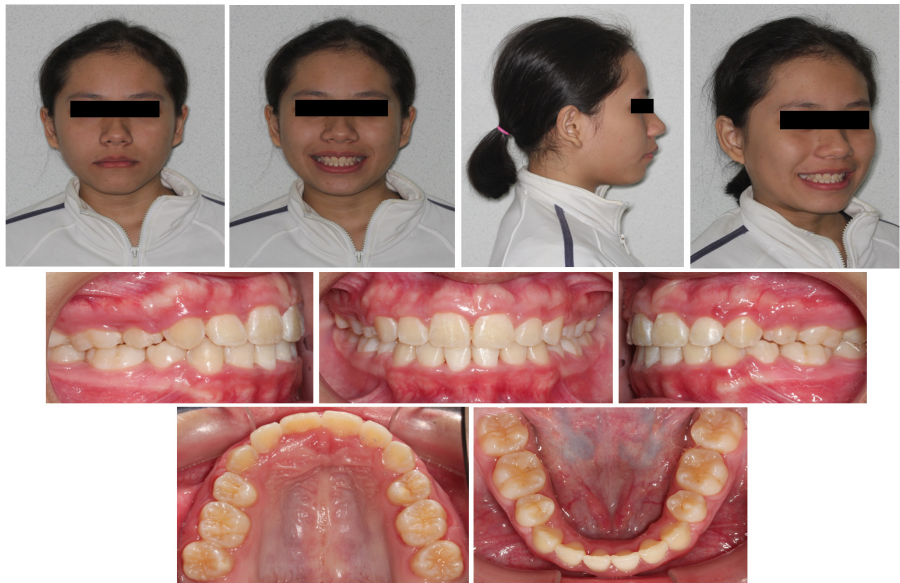

Figure 7: Post-treatment facial and intraoral photographs

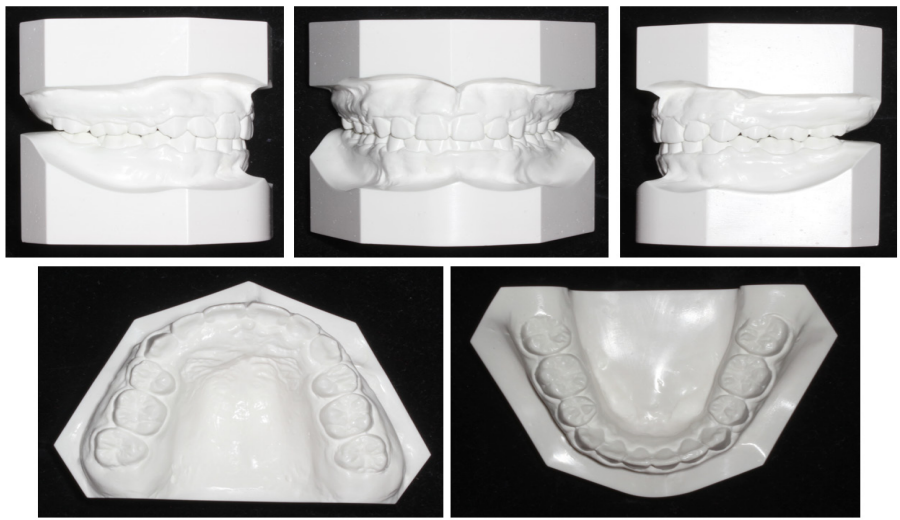


Figure 8: Post-treatment study models

DISCUSSION

This case was successfully treated with mini-implants as an absolute anchorage and the control of the upper incisors inclination to correct bimaxillary proclination. Orthodontic correction of the gummy smile requires intrusion of the anterior segments, which can be done by utility intrusion arch (13), Connecticut intrusion arch (14), J-hook headgear or mini-implants. The intrusion arch mechanics anchors against the posterior teeth. The counteractive movements on the posterior teeth could lead to loss of sagittal and vertical anchorages. Thus the maxillary molars may extrude, resulting in clockwise rotation of the mandible (13-14). The successful use of J-hook headgear requires good compliance and poses a higher risk of root resorption than do mini-implants (15).

Mini-implants have been placed between the upper central incisors (16), between the central and lateral incisors (15), and between the lateral incisors and canines (17) for direct anterior segment intrusion. The more medial the mini-implants, the more likely that intrusion forces would cause deformation of the archwire, resulting in labial tipping of the anterior teeth. Direct intrusion of the anterior segment with continuous archwire may also cause the occlusal plane to rotate counter-clockwise, which may lead to the extrusion of the posterior segment. The anterior segments can also be intruded indirectly from mini-implants placed posteriorly (18-19). These studies showed that the retraction force from the posted hooks to the mini-implants comprised a large horizontal retraction component and a small intrusive force (18-19). The degree of the intrusive force would have been dependent on the height of the mini-implant, but neither study specified the height for their mini-implant placement. Since the retraction force was below the centre of resistance, a clockwise moment can cause the incisors to tip lingually and affect the predictability of incisor intrusion. Shu *et al.* (2011) recommended adding a compensatory curve to the upper archwire to prevent excessive lingual crown tipping. They found that this mechanics was sufficient to correct the gummy smile for their patient (20).

In this case, the mini-implant was not considered necessary for the lower arch in anticipation of the high bone density of the mandible, which also gives the mandibular molars high anchorage value (21). As mandibular roots engage the high-density bone during mesial movement of the tooth, the rate of tooth movement declines (22). The mandibular superimposition confirmed very minimal mesial movement of the lower first molar, even without anchorage reinforcement. Vertically, levelling the curve of Spee had caused intrusion of the lower

anterior teeth and extrusion of the posterior teeth, as shown on Figure 6B, supporting overbite correction. The combination of incisor uprighting and lower molar extrusion by inclusion of the lower second molars contributed to the 1% increase in the lower face height ratio. The FMA reduced by 1°, which may be due to the compensatory posterior vertical growth of the growing adolescent.

In the maxilla where the bone density was lower, it was necessary to reinforce anchorage (21). This was done by placement of the transpalatal arch and mini-implants. Since the retraction force was buccal to the Cres of the posterior segments, the posterior teeth were at risk of moving inward due to the deformation of the rectangular archwire during the distal pull exerted by the coil springs (19). Such a deformation would have reduced the overall intermolar width, leading to the development of posterior crossbite. Therefore, the transpalatal arch had a role to play to control transverse anchorage.

Mini implants are efficient in retraction without extrusion (23). This is a very important consideration in treatment of gummy smile cases to prevent further gingival display during retraction as a result of incisor extrusion by conventional retraction mechanics. The first step in the biomechanical consideration for successful optimum retraction with concurrent intrusion and uprighting of the anterior segment was by determining the centre of resistance of the maxillary anterior teeth. The exact location of the centre of resistance is difficult to determine. Sia *et al.* (2007) suggested to locate the centre of resistance using the lateral cephalometric radiograph. The centre of resistance was estimated to be approximately 77% of the root length from the apex of the maxillary central incisor (24). Based on this practical clinical suggestion, in this case, the vertical distance of the centre of resistance was estimated to be 2-3mm below an imaginary horizontal line parallel to the archwire from the head of the inserted mini-implant.

In principle, bodily tooth movement is achieved when the force is applied at the same level of the centre of resistance since the centre of rotation is at infinity (Figure 9A(i)) (24). This is suitable for cases where the incisor inclination was acceptable. A horizontal retraction force applied below the centre of resistance causes the centre of rotation to be closer to the root and results in controlled lingual crown tipping (Figure 9A(ii)), while a horizontal force applied above the centre of resistance causes the centre of rotation to move closer to the tip of the crown, resulting in controlled labial crown tipping (Figure 9A(iii)) (24). The former is suitable in cases where the incisors are proclined while the latter is favourable in cases when the teeth were initially retroclined for incisor uprighting. Nonetheless, a

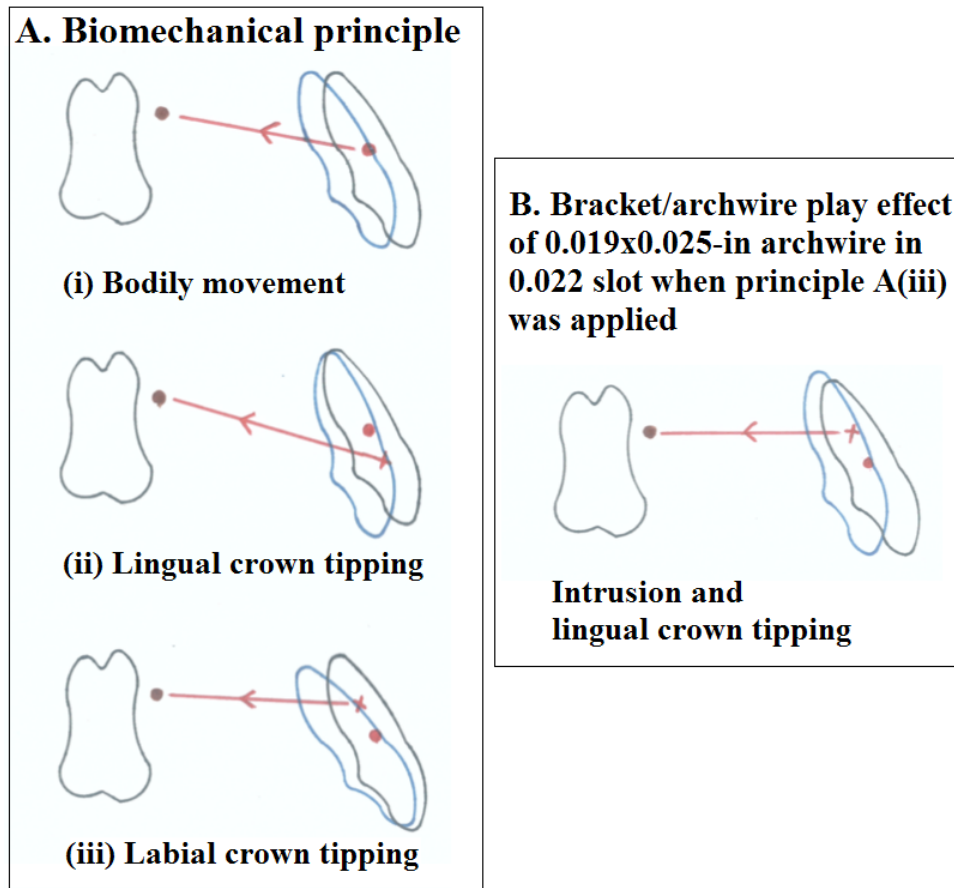


Figure 9: (A) Biomechanical principle of the force system during retraction: (i) If the retraction force is applied directly through the centre of resistance, the anterior teeth will move bodily; (ii) If the retraction force is applied below the centre of resistance, the anterior teeth will experience controlled lingual crown tipping. This may also cause extrusion of the upper incisors; and (iii) if the retraction force is above the centre of resistance, the anterior teeth will experience labial crown tipping. (B) If 0.019x0.025-in archwire is used in the 0.022 slot, the vertical play causes less lingual root tipping moment on the incisors during retraction. Retraction forces approximately 3mm above the centre of resistance cause controlled lingual crown tipping while at the same time allowing for optimum incisor intrusion.

finite element study demonstrated that these labio-lingual anterior tooth movements actually vary due to the influence of the bracket-archwire interplay (8). Tominaga *et al.* (2014) suggested that the vertical play impacts the movement of the anterior teeth in such a way that the greater the play between the archwire and the bracket, the weaker the normal forces to induce labial crown tipping. Their simulated study provided the principle used for this case for optimum anterior intrusion during retraction with controlled lingual crown tipping.

In this case, the applied force was placed from the mini-implant to the power arm parallel to the archwire and above this centre of resistance (Figure 9B). The intention was to create a moment that would be directed to intrude the maxillary anterior teeth during en-masse retraction. However, by having the force above the centre of resistance, the crown would have tipped labially during retraction, as shown in Figure 9A(iii), which would be unfavourable

for bimaxillary proclined cases. In order to prevent labial crown tipping, a rigid 0.019x0.025-in stainless steel working archwire was used in the 0.022-in bracket slot. Since the initial incisor inclination was significantly proclined (U1-SN at 132°), the torque expression from the bracket-archwire interface had reduced the inclination of the upper incisors. This bracket-archwire combination also provided 3 times more play in the vertical dimension compared to a 0.017x0.025-in stainless steel archwire in 0.018-in slot (8). Thus there was less lingual root tipping moment during retraction (8). A finite element study by Tominaga *et al.* demonstrated that retraction force applied on a power arm in a 0.019x0.025-in stainless steel archwire in the 0.022-in bracket slot at approximately 3.1mm above the centre of resistance would induce controlled lingual crown tipping; at 4.4mm above the centre of resistance it would induce bodily movement while placement at 5.8mm above the centre of resistance would cause

controlled lingual root tipping (8). The heights of the retraction force were much lower with stainless steel archwire of smaller dimensions (0.017x0.025-in) in the 0.018-in bracket slot, which were 1.1mm, 1.9mm and 2.3mm above the centre of resistance, to induce controlled lingual crown tipping, bodily movement and lingual root tipping. Since this case used 0.019x0.025-in stainless steel in the 0.022-in bracket slot, the retraction force placed just above the centre of resistance induced controlled lingual crown tipping and encouraged retroclination of the anterior segment to a more upright position.

Retraction and uprighting of the anterior teeth also reduced lip procumbence and improved the lip profile.

CONCLUSION

This case demonstrated that the need to address the vertical maxillary excess by orthognathic surgery was avoided by use of mini-implants and carefully planned positioning of the retraction force to maximise upper anterior segment intrusion to reduce the gummy smile. The 0.019x0.025-in stainless steel archwire in 0.022-in slot provided the vertical play to favour lingual crown tipping for this bimaxillary incisor proclination case during retraction despite having the forces above the centre of resistance for concurrent anterior segment intrusion. The clinical outcome concurred with previous finite element prediction (8). Since it took only 17 months to complete this case, this biomechanics can be considered efficient to address gummy smile with proclined incisors.

ACKNOWLEDGMENT

The authors would like to thank Alena Sanusi for helpful comments and the staff of Klinik Pergigian Helmy for assistance.

REFERENCES

1. Sarver, D.M., The importance of incisor positioning in the esthetic smile: the smile arc. *Am J Orthod Dentofacial Orthop*, 2001; 120(2): 98-111.
2. Waldrop, T.C., Gummy Smiles: The Challenge of Gingival Excess: Prevalence and Guidelines for Clinical Management. *Seminars in Orthodontics*, 2008; 14(4): 260-271.
3. Garber, D.A. and M.A. Salama, The aesthetic smile: diagnosis and treatment. *Periodontol* 2000, 1996; 11: 18-28.
4. Siatkowski, R.E., Loss of anterior torque control due to variations in bracket slot and archwire dimensions. *J Clin Orthod*, 1999; 33(9): 508-10.
5. Upadhyay, M., Yadav, S., Nagaraj, K., Patil, S., Treatment effects of mini-implants for en-masse retraction of anterior teeth in bialveolar dental protrusion patients: a randomized controlled trial. *Am J Orthod Dentofacial Orthop*, 2008; 134(1): 18-29 e1.
6. Upadhyay, M., S. Yadav, and R. Nanda, Vertical-dimension control during en-masse retraction with mini-implant anchorage. *Am J Orthod Dentofacial Orthop*, 2010; 138(1): 96-108.
7. Park, H.S., S.K. Lee, and O.W. Kwon, Group distal movement of teeth using microscrew implant anchorage. *Angle Orthod*, 2005; 75(4): 602-9.
8. Tominaga, J.Y., Ozaki, H., Chiang, P. C., Sumi, M., Tanaka, M., Koga, Y., Bourauel, C., Yoshida, N., Effect of bracket slot and archwire dimensions on anterior tooth movement during space closure in sliding mechanics: a 3-dimensional finite element study. *Am J Orthod Dentofacial Orthop*, 2014; 146(2): 166-74.
9. Kirschen, R.H., A. O'Higgins E, and R.T. Lee, The Royal London Space Planning: an integration of space analysis and treatment planning: Part I: Assessing the space required to meet treatment objectives. *Am J Orthod Dentofacial Orthop*, 2000; 118(4): 448-55.
10. Lin, J., Chapter 4: Mini-Screw as Skeletal Anchorage, in *Creative Orthodontics: Blending the Damon System & TADs to manage difficult malocclusions* 2007; Yong Chieh: Taiwan. 241-275.
11. Farnsworth, D., Rossouw, P. E., Ceen, R. F., Buschang, P. H., Cortical bone thickness at common miniscrew implant placement sites. *Am J Orthod Dentofacial Orthop*, 2011; 139(4): 495-503.
12. Tominaga, J.Y., Tanaka, M., Koga, Y., Gonzales, C., Kobayashi, M., Yoshida, N., Optimal loading conditions for controlled movement of anterior teeth in sliding mechanics. *Angle Orthod*, 2009; 79(6): 1102-7.
13. Polat-Ozsoy, O., Arman-Ozcirpici, A., Veziroglu, F., Cetinsahin, A., Comparison of the intrusive effects of miniscrews and utility arches. *Am J Orthod Dentofacial Orthop*, 2011; 139(4): 526-32.
14. Senisik, N.E. and H. Turkkahraman, Treatment effects of intrusion arches and mini-implant systems in deepbite patients. *Am J Orthod Dentofacial Orthop*, 2012; 141(6): 723-33.
15. Deguchi, T., Murakami, T., Kuroda, S., Yabuuchi, T., Kamioka, H., Takano-Yamamoto, T., Comparison of the intrusion effects on the

- maxillary incisors between implant anchorage and J-hook headgear. *Am J Orthod Dentofacial Orthop*, 2008; 133(5): 654-60.
16. Kim, T.W., H. Kim, and S.J. Lee, Correction of deep overbite and gummy smile by using a mini-implant with a segmented wire in a growing Class II Division 2 patient. *Am J Orthod Dentofacial Orthop*, 2006; 130(5): 676-85.
 17. Kaku, M., Murakami, T., Kuroda, S., Yabuuchi, T., Kamioka, H., Takano-Yamamoto, T., Gummy smile and facial profile correction using miniscrew anchorage. *Angle Orthod*, 2012; 82(1): 170-7.
 18. Lee, K.J., Park, Y. C., Hwang, C. J., Kim, Y. J., Choi, T. H., Yoo, H. M., Kyung, S. H., Displacement pattern of the maxillary arch depending on miniscrew position in sliding mechanics. *Am J Orthod Dentofacial Orthop*, 2011; 140(2): 224-32.
 19. Upadhyay, M., Yadav, S.,Nagaraj, K., Nanda, R., Dentoskeletal and soft tissue effects of mini-implants in Class II division 1 patients. *Angle Orthod*, 2009; 79(2): 240-7.
 20. Shu, R., L. Huang, and D. Bai, Adult Class II Division 1 patient with severe gummy smile treated with temporary anchorage devices. *Am J Orthod Dentofacial Orthop*, 2011; 140(1): 97-105.
 21. Chugh, T., Ganeshkar, S. V., Revankar, A. V., Jain, A. K., Quantitative assessment of interradicular bone density in the maxilla and mandible: implications in clinical orthodontics. *Prog Orthod*, 2013; 14: 38.
 22. Roberts, W., Bone physiology, metabolism, and biomechanics in orthodontic practice, in *Orthodontics: Current Principles and Techniques*, V.R. Graber TM, Vig KWL, Editor 2005, Mosby: St Louis. 221–92.
 23. Ruellas, A.C., M.M. Pithon, and R.L. dos Santos, Maxillary incisor retraction: evaluation of different mechanisms. *Dental Press J Orthod*, 2013; 18(2): 101-7.
 24. Sia, S., Y. Koga, and N. Yoshida, Determining the center of resistance of maxillary anterior teeth subjected to retraction forces in sliding mechanics. An in vivo study. *Angle Orthod*, 2007; 77(6): 999-1003.

Corresponding author:

Wan Nurazreena Wan Hassan

*Department of Paediatric Dentistry and Orthodontics,
Faculty of Dentistry,*

University of Malaya,

50603 Kuala Lumpur, Malaysia.

Email: wannurazreena@um.edu.my;

Telephone: +603-79674802;

Fax: +603-79674530.
